



12TH INTERNATIONAL CONFERENCE ON EMERGENCY MEDICINE

ICEM 2008

Global Needs, Global Responses

3-6 April 2008

San Francisco, California, USA

SU-209

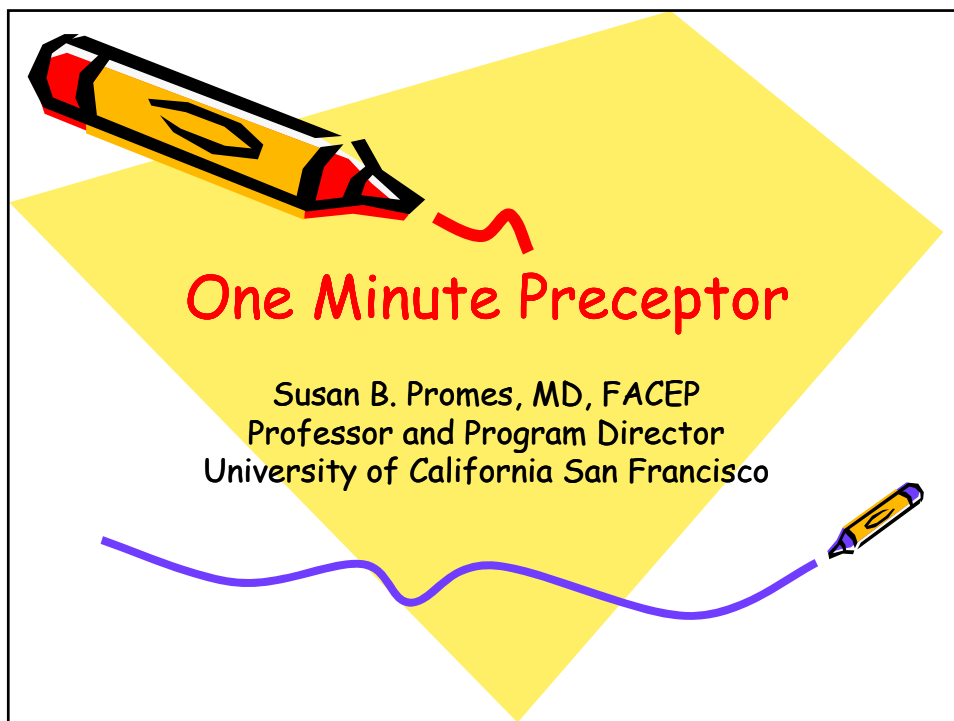
One-Minute Preceptor Model for Clinical Teaching

Presented by:

Dr. Susan B. Promes



April 2008



One Minute Preceptor Model

- Five-step microskills model of clinical teaching described in 1992
 - Fosters ownership of clinical problems
 - Allows learner and teacher to identify knowledge gaps and focus learning
- Particularly helpful to newer teaching clinicians

Neher JO, et al. Fam Med
2003;35(6):391-3

Five Microskills

- #1 Get a commitment
- #2 Probe for supporting evidence
- #3 Teach general rules
- #4 Reinforce what was right
- #5 Correct mistakes and discuss next steps



Neher JO, et al. Jnl of Amer
Board Family Practice 1992



Get a Commitment

Good Examples:

- What do you think is going on?
- Why do you think this patient has been non-compliant?
- What do you want to do next in the work-up?



Get a Commitment

Bad Examples:

- Sounds like pneumonia, don't you think?
- Anything else?



Probe for Supporting Evidence

Helpful approaches:

- What led you to that conclusion?
- What else did you consider?
- Why did you rule out that choice?
- What are the major findings that led to that conclusion?



Probe for Supporting Evidence

Non-helpful approaches:

- I disagree. Do you have any other ideas?
- This seems like a classic case of...



Teach General Rules

Good Example:

- If the patient only has cellulitis, an incision and drainage is not possible. You will have to wait for the area to become fluctuant to drain it.



Teach General Rules

Bad Examples:

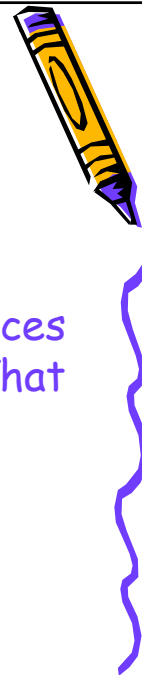- The patient has heart failure and needs a diuretic. Don't start the beta blocker now.



Reinforce What They Did Right

Good Examples:

- You considered the patient's finances when you chose the medication. That will greatly contribute to his compliance.



Reinforce What They Did Right

Bad Examples:

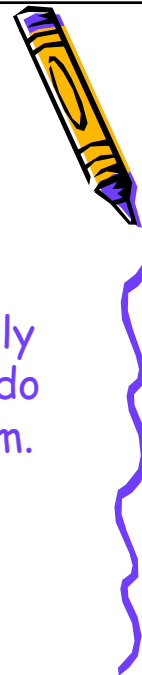- You are right that was a good decision.
- Nice presentation.



Correct Mistakes and Discuss Next Steps

Helpful:

- I agree that the patient is probably drug seeking, but we still need to do a careful history and physical exam.



Correct Mistakes

Not Helpful:

- You did what?
- What were you thinking?



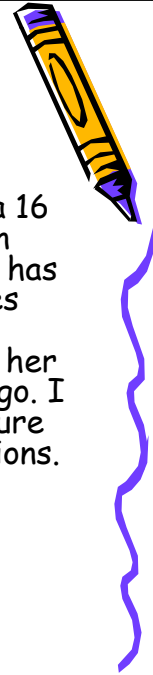
Five Errors Commonly Made with this Model

- Taking over the case
- Not allowing sufficient wait time
- Giving lectures
- Asking questions that lead to a particular answer
- Pushing a learner too hard



Case 1

Medical Student: "I just finished examining a 16 year-old girl. She has been complaining of pain when she urinates for the past few days. She has never had a urinary tract infection. She denies burning on urination, abdominal pain, fever or seeing blood in her urine. She says she thinks her last menstrual period was a couple of weeks ago. I don't know if she is sexually active. I wasn't sure if I was supposed to ask those kinds of questions. She is here with her mother."




Case 1 (cont.)

"On physical exam, she looked well to me. She was afebrile and the rest of her vital signs were O.K. Her HEENT exam was normal. Her lungs were clear and her heart was regular without any murmurs. Her abdomen was soft and not tender and I didn't think her spleen or liver were enlarged. That's all I examined."



Case 2

EM Resident: "I have a case of an 18 year-old G1P0 single, white female with an EGA 31 3/7 weeks who presents with swelling. She incidentally complains of a frontal headache along with the swelling in her ankles and hands. Her blood pressure was 180/100. She looks well. Obviously pregnant with no abdominal pain. Pelvic exam demonstrated a closed, thick cervix with no abnormal discharge. She has fetal heart tones by bedside ultrasound at 160 bpm. She has 3+ edema."



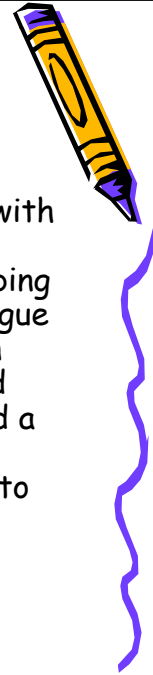Case 3

Intern: "I just don't understand these electrolytes on my patient, Mr. T. He's the 36 year old man with a history of alcoholic hepatitis. His sodium is 133, potassium 2.9, Chloride 102, and bicarbonate 18. He looks O.K., but still has some nausea and a fever of 101.2. BP is 106/68, pulse 90. On exam he is jaundiced, and has mild RUQ tenderness but no rebound. His wbc is 16.8, unchanged from previous. Why do you think his potassium is so low? We've been putting some in his IV fluid."



Case 4

Medical Student: "I have a 57 year old male with a history of hypertension, one pack per day smoker who presents with dyspnea when climbing hills to work. Further questioning reveals a vague tightening in the anterior chest with exertion that the patient rates as 6/10. He first noted this 2 months ago, now occurring daily. He had a pain free, comfortable exam. BP 140/90, EKG normal. I'm wondering if we should admit him to the hospital."



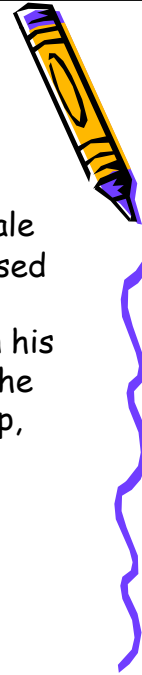
Case 5

Senior EM Resident: "I have a five-year-old boy with fever and ear pain for five days. His tympanic membrane are red. I'd like to treat him with amoxicillin and Actifed."



Case 6

Rotating Resident: "I have a 35 year old female with two teenagers who reports being depressed and having suicidal ideations. The patient quit work three months ago to help her husband in his business and to assist in the home remodel. She began worrying about money and has lost sleep, appetite and energy."



Case 7

EM Resident: "I just saw a four year-old boy in Fast Track with a complaint of ear pain and fever for the past 24 hours. He has a history of prior episodes of otitis media, usually occurring whenever he has an upper respiratory tract infection. For the past two days, he has had a runny nose and mild cough and yesterday, he began to have a low grade fever and complained that his right ear was hurting. His mother gave him Tylenol last night and when he got up this morning. He has no allergies to medication."



Case 7 (cont.)

"On physical exam, he appeared in no acute distress and was alert and cooperative. His temperature was 38.5 C. His HEENT exam was remarkable for a snotty nose and I think his right tympanic membrane was red, but I'm not sure. It looked different from the left one. His throat was not infected. His neck was supple without adenopathy. His lungs were clear and his heart had no murmur. I didn't see any rashes or skin lesions."

